

## Anti-ulcer activity of herbo-mineral formulation (Asecure capsule) against experimentally induced acute and chronic gastric ulcers in rats

Hardik Soni<sup>1\*</sup>, Ankur Shah<sup>2</sup>, Arindam Paul<sup>2</sup>, Ghanshyam Patel<sup>1</sup>

<sup>1</sup>Vasu Research Centre, A Division of Vasu Healthcare Pvt. Ltd., 896/A, G.I.D.C., Makarpura, Vadodara, Gujarat - 390 010, India.

<sup>2</sup>Department of Pharmacology, Babaria Institute of Pharmacy, BIT education campus, Vadodara-Mumbai NH#8, Varnama, Vadodara, Gujarat - 391 240, India.

### ABSTRACT

**Background:** This study was aimed to investigate anti-ulcer activity of a herbo-mineral formulation (Asecure capsule) in ethanol-induced acute gastric ulcer and acetic acid-induced chronic gastric ulcer.

**Materials and Methods:** Absolute methanol (5 mL/kg, p.o.) was administered for development of acute gastric ulcer. In another model, 50% acetic acid was exposed to serosal surface of stomach to produce chronic gastric ulcer. For each experiment, animals were divided into three groups where each group was consisting of six animals. Group-I, II and III were considered as Normal control, Disease control and test drug treated respectively. Herbo-mineral formulation (Asecure Capsule) was administered at 100 mg/kg/day, orally. Ulcer index, gastric wall mucus content, lipid peroxidation level in stomach tissue and tissue anti-oxidant parameters like superoxide dismutase, reduced glutathione and catalase enzyme activity were carried out for both experimental studies. Histopathology of stomach tissue was also performed. Statistical calculations were done by analysis of variance (ANOVA) followed by *post hoc* Bonferroni's test.

**Results:** Induction of ethanol and acetic acid caused significant alteration in ulcer index, gastric wall mucus content and lipid peroxidation level in comparison to normal control group whereas treatment of Asecure capsule showed significant cyto-protection and recovery against ethanol and acetic acid induced acute and chronic ulcer respectively. Treatment with Asecure capsule also showed significant increase in level of antioxidant enzymes in comparison of disease control groups. Histopathology of stomach showed remarkable cyto-protection.

**Conclusion:** On the basis of present data it can be concluded that Asecure capsule possesses significant anti-ulcer activity against exposure to a noxious agent like ethanol and acetic acid. The observed effect be due to synergistic anti-oxidant property of ingredients of the herbo-mineral formulation.

**Key words:** Herbo-mineral, ethanol and acetic acid induced gastric ulcer, anti-ulcer activity.

**Citation:** Soni H, Shah A, Paul A, Patel G. Anti-ulcer activity of herbo-mineral formulation (Asecure capsule) against experimentally induced acute and chronic gastric ulcers in rats. *Int J Pharmacol and Clin Sci* 2014;3:61-7.

### INTRODUCTION

Peptic ulcer is one of the common disease affecting millions of people around the world. It is affecting nearly 10% of world population.<sup>[1]</sup> Evidences suggest that reactive oxygen species (ROS) play an important role in the pathophysiological processes of acute and chronic gastric lesions.<sup>[2]</sup> Excess alcohol consumption has been found associated with multiple pathologies at all levels.<sup>[3]</sup> Among the different body's systems, alcohol affects

gastrointestinal (GI) tract particularly. When alcohol is consumed, it first passes through the various segments of the gastrointestinal (GI) tract. Accordingly, alcohol may interfere with the structure as well as the function of GI-tract which can result in a broad spectrum of acute

Received : 19 - 06 - 2014

Revised : 05 - 08 - 2014

Accepted : 19 - 10 - 2014

\* Correspondence : hsoni@vasuresearch.com

Conflict of interest: Nil

Source of support : Nil

Copyright: © 2014 Journal. All rights reserved.

and chronic diseases, such as acute gastrointestinal bleeding (from lesions in the stomach or small intestine).<sup>[4]</sup> *Helicobacter pylori* (*H. pylori*) infection, severe stress and exposure to various chemical and NSAIDs also play important role in development of gastric mucosal lesions.<sup>[5]</sup>

Test drug (Herbo-mineral formulation - Asecure Capsule) is such an Ayurvedic proprietary formulation which contains extract of *Emblica officinalis* (Amalaki) fruit,<sup>[6,7]</sup> *Asparagus racemosus* (Shatavari) root,<sup>[8]</sup> *Glycyrrhiza glabra* (Yasthimadhu) root,<sup>[1,9]</sup> *Tinospora cordifolia* (Guduchi) stem,<sup>[10]</sup> *Withania somnifera* (Ashwagandha) root,<sup>[11,12]</sup> *Zingiber officinale* (Shunthi) rhizome<sup>[13,14]</sup> and powder of Sodii carbonas (Swarjikakshar) Mineral <sup>[15]</sup> and Cow's ghee.<sup>[16]</sup> It is developed and standardized by Vasu Research Centre (A division of Vasu Healthcare Pvt. Ltd.), Vadodara. Majority of ingredients of the Herbo-mineral formulation (Asecure Capsule), individually are well reported in Ayurvedic texts and scientific research publications for anti-ulcer activity. However, no such evidence was found which proves efficacy of such combination.

In the present study, an attempt was made to investigate anti-ulcer activity of Asecure Capsule in ethanol and acetic acid induced acute and chronic gastric ulcer respectively.

## MATERIALS AND METHODS

### Experimental Animals

Wistar albino rats of 200-250 g were used and acclimatized to the experimental room having ambient temperature ( $23 \pm 2^\circ\text{C}$ ), controlled humidity ( $55 \pm 5\%$ ) conditions, and 12 h light and dark cycle. Animals were caged in polypropylene cages with maximum of three animals per cage. The rats were fed with standard food pellets and water *ad libitum*. Study was conducted after obtaining approval by Institutional Animal Ethical Committee (IAEC) (Babaria Institute of Pharmacy, M.Ph Sem-IV/12-13/12) as per the guidance of Committee for the Purpose of Control and Supervision of

Experiments on Animal (CPCSEA), Ministry of Social Justice and Empowerment, Government of India.

### Administration of Test Drug and Dosage

The test drug (Asecure Capsule) was prepared at Vasu Research Centre, A division of Vasu Healthcare Pvt. Ltd., Vadodara, Gujarat, India. Dose of the test drug was fixed by extrapolating the human dose to laboratory animals, based on body surface area ratio as per the table of Paget and Barnes.<sup>[17]</sup> Test drug was administered at 100 mg/kg/day (p.o) in form of suspension by mixing with distilled water.

### Ethanol-induced acute gastric ulcer <sup>[18]</sup>

The selected animals were divided in to three groups and each group consisted of six animals. Group-I: Served as normal control and received distilled water as vehicle; Group-II: Served as disease control and received absolute ethanol (5 mL/kg, p.o.); Group-III: Served as test drug (Herbo-mineral formulation) treated group and received Herbo-mineral formulation (100 mg/kg/day, p.o.) + absolute ethanol (5 mL/kg, p.o.).

Herbo-mineral formulation was administered orally for 7 days in selected animals of Group-III prior to administration of absolute alcohol. On the 7<sup>th</sup> day, animals in each group were fasted for 18 h after their assigned treatment. On the 8<sup>th</sup> day, single dose of absolute ethanol (5 mL/kg, p.o.) was administered in Group-II and Group-III. One hour after administration of absolute ethanol, the animals of all groups were sacrificed under ether anesthesia and abdomen was opened by midline incision. Stomach was removed and cut along the greater curvature, washed with normal saline and stretched on paraffin bed. The glandular part was observed for ulceration and ulcer index<sup>[19]</sup> was determined. The samples of stomach tissue were analyzed to determine gastric wall mucus content,<sup>[20]</sup> lipid peroxidation (MDA),<sup>[21]</sup> reduced glutathione,<sup>[22]</sup> superoxide dismutase<sup>[23]</sup> and catalase activity.<sup>[24]</sup>

**Acetic acid-induced chronic gastric ulcer<sup>[25]</sup>**

The selected animals were divided into three groups and each group consisted of six animals. Group-I: Served as normal control and received distilled water as vehicle; Group-II: Served as disease control and exposed to 0.06 mL, 50 % acetic acid for 60s; Group-III: Served as test drug (Herbo-mineral formulation) treated group and received Herbo-mineral formulation (100 mg/kg/day, p.o.) + exposed to acetic acid.

Gastric ulcers were induced using the method described by Okabe *et al.* with some modifications. Selected rats were deprived of food 18 h prior to the experiment but were allowed free access to water. Under ether anesthesia a midline abdominal incision was made and stomach was exposed. 50% Glacial acetic acid (0.06 mL) was applied topically onto the serosal surface using a cylindrical mold (5 mm internal diameter), which was allowed to remain there for 60s. The acid solution was then removed by rinsing the mold with normal saline to prevent possible damage to the surrounding tissues close to the point of application. After removal of the acetic acid, the abdomen was closed by sutures. This method was found to result in the formation of chronic ulceration of mucosa and sub-mucosa within the area of acetic acid application.

Herbo-mineral formulation at dose 100 mg/kg/day was given orally 4 h after the application of acetic acid and continued up to 10 days in Group-III. On the 10<sup>th</sup> day, animals in each group were fasted for 18 h after their assigned treatment. On 11<sup>th</sup> day, animals of all groups were sacrificed under ether anesthesia and abdomen was opened by midline incision. Stomach was removed and cut along the greater curvature, washed with normal saline and stretched on paraffin bed. The glandular part was observed for ulceration and ulcer index<sup>[19]</sup> was determined. The samples of stomach tissue were analyzed to determine gastric wall mucus

content,<sup>[20]</sup> lipid peroxidation (MDA),<sup>[21]</sup> reduced glutathione,<sup>[22]</sup> superoxide dismutase<sup>[23]</sup> and catalase activity.<sup>[24]</sup>

**Ulcer index<sup>[19]</sup>**

The ulcers were given scores based on their intensity as follows: 0 = no ulcer, 1 = superficial mucosal erosion, 2 = deep ulcer or transmural necrosis, 3 = perforated or penetrated ulcer. Gradation was provided separately as follow: 0 = No visible ulcer, 1 = Maximum diameter of 1-2 mm, 2 = Maximum diameter of 2-3 mm, 3 = Maximum diameter of 3-4 mm, 4 = Maximum diameter of 4-5 mm, 5 = An ulcer over 5 mm in diameter. The ulcer index (UI) was calculated using the following equation;

$$UI = \text{Gradation} \times \text{Ulcer intensity}$$

**Gastric wall mucus content<sup>[20]</sup>**

1cm<sup>2</sup> portion of glandular segment of stomach was cut and transferred to 10 mL of 0.1% w/v alcian blue solution and allowed to stain for 2 h in alcian blue solution. Excess dye was removed by rinsing the tissue with 10 mL of 0.25 M sucrose solution. Dye complexed with gastric wall mucus was extracted with 0.5M MgCl<sub>2</sub> for 2 h. The blue extract was then shaken vigorously with an equal volume of diethyl ether and the resulting emulsion was centrifuged. The optical density of Alcian blue in the aqueous layer was read against a buffer blank at 580 nm using a spectrophotometer. The quantity of Alcian blue extract per gram wet stomach was then calculated from a standard curve.

**Histopathology of Stomach**

Stomach from additional two animals of each group was removed after sacrificing under anesthesia. It was collected in 10% formalin solution and immediately processed by paraffin technique. Section of approximately 5µm thickness was cut and stained by hematoxylin and eosin (H&E). Sections were examined under microscope to evaluate structural changes. Histopathology of stomach was carried out in both

experimental models viz. ethanol-induced acute gastric ulcer and acetic acid-induced chronic gastric ulcer.

### Statistical Analysis

All values are expressed in Mean  $\pm$  Standard Error of Mean (SEM). Different groups were compared with analysis of variance (ANOVA) followed by *post hoc* Bonferroni's test using computer based software graph pad prism 5. Differences were considered to be statistically significant when  $P < 0.05$ .

## RESULTS

### Effect on ethanol-induced acute gastric ulcer (Table 1)

The severity of ethanol induced ulceration was found significantly protected ( $P < 0.01$ ) by test drug in comparison of disease control group. Gastric wall mucus content was found significantly decreased due to administration of ethanol. Pre-treatment of test drug showed significant ( $P < 0.05$ ) protection against loss occurred in gastric wall mucus content due to administration of ethanol.

Antioxidant parameters like reduced glutathione, superoxide dismutase and catalase enzyme activity of stomach was significantly reduced due to administration of ethanol. Test drug treated group showed significant increase in all antioxidant parameters when compared with diseases control group.

Ethanol caused significant ( $P < 0.01$ ) increase in lipid peroxidation level in comparison of normal control group. Test drug treated

group significantly ( $P < 0.01$ ) reduced lipid peroxidation level in comparison to disease control group.

Histopathology of stomach of normal control rat showed normal cyto-architecture of cells and normal gastric mucosa. Ethanol induction in disease control group caused heavy mucosal damage, oedema and cell necrosis. Test drug treated group showed mild oedema and mild to moderate mucosal damage which was comparatively quite lower than disease control group (Fig. 1).

### Effect on acetic acid-induced chronic gastric ulcer (Table 2)

Exposure of acetic acid to gastric wall cause chronic ulceration which was significantly observed in disease control group. In test drug treated group there was highly significant ( $P < 0.001$ ) reduction in ulcer index as compared to disease control group. Gastric wall mucus content was also found to be significantly decreased due to exposure of acetic acid. Test drug treated group showed significant ( $P < 0.01$ ) increase in gastric wall mucus content as compared to disease control group.

Antioxidant parameters like reduced glutathione, superoxide dismutase and catalase enzyme activity of stomach were significantly reduced due to exposure of acetic acid. Test drug treated group was observed having significantly increased level of antioxidant parameters. It also showed remarkable protection against elevation of lipid peroxidation level while compared to disease control group.

**Table 1: Effect of Herbo-mineral formulation in ethanol induced acute gastric ulcer in rats**

Group (n=6)	Ulcer index	Gastric wall mucus content ( $\mu\text{g/mL}$ )	Reduced glutathione ( $\mu\text{g/g}$ of tissue)	Superoxide dismutase ( $\mu\text{g/g}$ of tissue)	Catalase enzyme activity ( $\mu\text{mole H}_2\text{O}_2$ consumed/min/g of tissue)	Lipid peroxidation (nmole/g of tissue)
Normal control	0.00 $\pm$ 0.00	393.60 $\pm$ 29.20	146.15 $\pm$ 12.61	344.32 $\pm$ 31.80	121.66 $\pm$ 11.44	29.13 $\pm$ 3.57
Disease control	5.81 $\pm$ 0.36 <sup>§</sup>	181.93 $\pm$ 15.75 <sup>†</sup>	80.27 $\pm$ 6.10 <sup>  </sup>	100.25 $\pm$ 12.86 <sup>§</sup>	58.74 $\pm$ 4.00 <sup>§</sup>	63.50 $\pm$ 6.22 <sup>§</sup>
Herbo-mineral formulation	3.72 $\pm$ 0.38 <sup>†</sup>	294.12 $\pm$ 27.16 <sup>*</sup>	134.14 $\pm$ 10.87 <sup>†</sup>	302.48 $\pm$ 11.80 <sup>  </sup>	114.48 $\pm$ 7.97 <sup>  </sup>	38.50 $\pm$ 3.44 <sup>†</sup>

Values are expressed in Mean  $\pm$  SEM, \* $p < 0.05$ , <sup>†</sup> $p < 0.01$ , <sup>||</sup> $p < 0.001$  vs. disease control.

<sup>‡</sup> $p < 0.05$ , <sup>||</sup> $p < 0.01$ , <sup>§</sup> $p < 0.001$  vs. normal control.

Histopathology of stomach of normal control rat showed normal cyto-architecture. Administration of acetic acid in disease control group produced severe epithelial cells destruct-

tion, oedema and necrosis. Whereas, the test drug treatment showed remarkable cyto-protection against acetic acid induced chronic gastric degenerative changes.

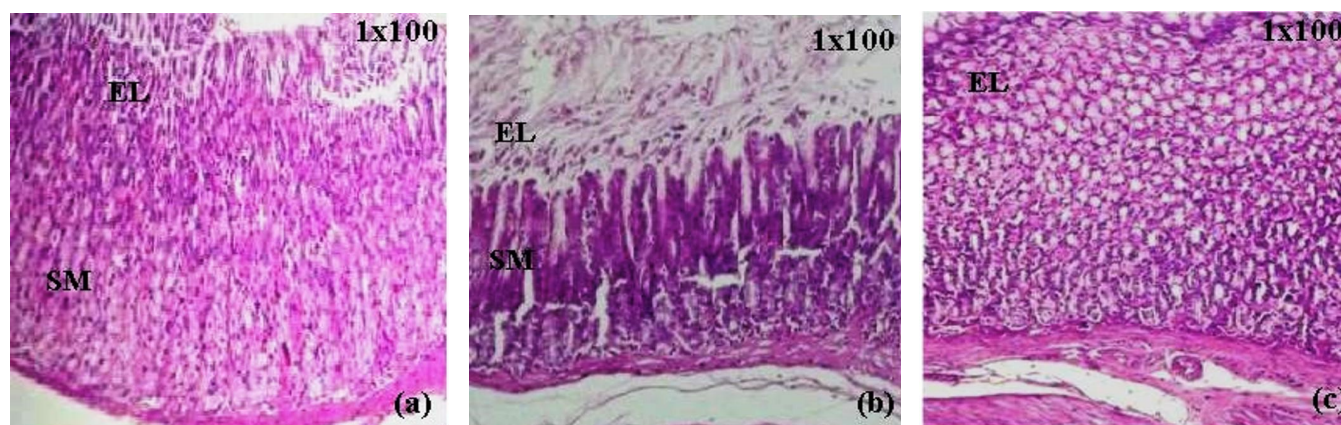
**Table 2: Effect of Herbo-mineral formulation in acetic acid induced chronic gastric ulcer in rats.**

Group (n=6)	Ulcer index	Gastric wall mucus content ( $\mu\text{g/mL}$ )	Reduced glutathione ( $\mu\text{g/g}$ of tissue)	Superoxide dismutase ( $\mu\text{g/g}$ of tissue)	Catalase enzyme activity ( $\mu\text{mole H}_2\text{O}_2$ consumed/min/g of tissue)	Lipid peroxidation (nmole/g of tissue)
Normal control	0.00 $\pm$ 0.00	398.77 $\pm$ 30.46	240.51 $\pm$ 7.29	393.14 $\pm$ 25.14	398.77 $\pm$ 30.46	25.79 $\pm$ 1.60
Disease control	5.83 $\pm$ 0.22 <sup>§</sup>	159.83 $\pm$ 15.67 <sup>§</sup>	128.55 $\pm$ 11.15 <sup>  </sup>	197.88 $\pm$ 19.97 <sup>§</sup>	159.83 $\pm$ 15.67 <sup>§</sup>	68.14 $\pm$ 5.61 <sup>§</sup>
Herbo-mineral formulation	1.11 $\pm$ 0.09 <sup>  </sup>	288.51 $\pm$ 22.84 <sup>†</sup>	203.84 $\pm$ 19.28 <sup>*</sup>	303.45 $\pm$ 23.41 <sup>†</sup>	288.51 $\pm$ 22.84 <sup>†</sup>	32.04 $\pm$ 2.8 <sup>  </sup>

Values are expressed in Mean  $\pm$  SEM, \*  $p < 0.05$ , †  $p < 0.01$ , ||  $p < 0.001$  vs. disease control.

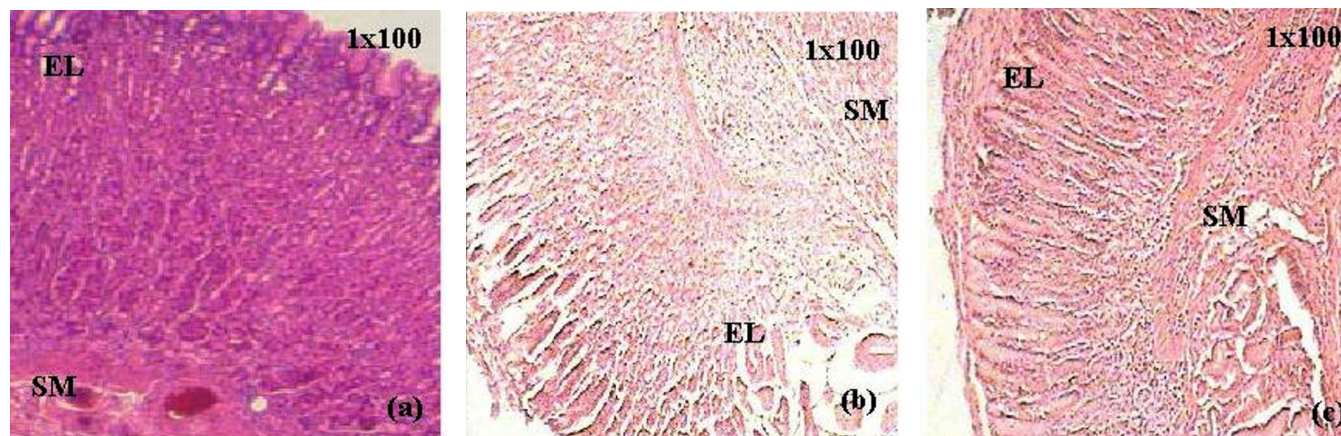
<sup>‡</sup>  $p < 0.05$ , <sup>||</sup>  $p < 0.01$ , <sup>§</sup>  $p < 0.001$  vs. normal control.

**Figure 1: Effect of Herbo-mineral formulation on histopathology of stomach in ethanol induced acute gastric ulcer**



EL - Epithelial layer, SM - Submucosal layer, 1 X 100 - Microscope resolution. (a) - Normal control showing normal cytoarchitecture and normal gastric mucosa; (b) - Disease control showing severe mucosal damage, oedema and necrosis; (c) - Herbo-mineral formulation treated showing regeneration of epithelial cells and prevention against ethanol induced acute gastric mucosal damage.

**Figure 2: Effect of Herbo-mineral formulation on histopathology of stomach in acetic acid induced chronic gastric ulcer**



EL - Epithelial layer, SM - Submucosal layer, 1 X 100 - Microscope resolution. (a) - Normal control showing normal cytoarchitecture; (b) - Disease control showing severe epithelial cells destruction, oedema and necrosis; (c) - Herbo-mineral formulation treated showing cyto-protection against acetic acid induced chronic gastric degenerative changes.

## DISCUSSION

The anti-ulcer activity of Herbo-mineral formulation was investigated against ethanol- and acetic acid-induced acute and chronic gastric ulcers model in rats respectively. Ethanol serves as the most common ulcerogenic agent. When it is given orally to rats it produces severe gastric hemorrhagic erosions.<sup>[26]</sup> The genesis of ethanol-induced gastric lesions is multifactorial where the depletion of gastric wall mucus content is one of the involved factors.<sup>[27]</sup> The acetic acid-induced chronic ulcer model is another classic model for evaluation of anti-ulcer activity. Exposure to acetic acid develops vascular injury, oedema, hemorrhagic spots, epithelial thickening and necrotic lesions in stomach.<sup>[28]</sup>

Induction of ethanol and acetic acid caused significant ulceration which was measured and interpreted as ulcer index. Induction of these chemicals also altered gastric wall mucus content and lipid peroxidation level in comparison to normal control group. In present study, treatment of Herbo-mineral formulation was observed providing significant cyto-protection against noxious effect of ethanol and acetic acid.

In both the experimental studies, disease control rats showed significant decrease in superoxide dismutase, reduced glutathione levels and catalase enzyme activity as compared to normal control, indicating a dysfunction in antioxidant defensive system. Treatment with Herbo-mineral formulation exhibited significant increase in level of antioxidant enzymes in comparison of disease control groups. An antioxidant property of Herbo-mineral formulation may be attributed to its ingredients like *Embllica officinalis* (Amalaki) fruit,<sup>[6,7]</sup> *Asparagus racemosus* (Shatavari) root,<sup>[8]</sup> *Glycyrrhiza glabra* (Yasthimadhu) root,<sup>[1,9]</sup> *Tinospora cordifolia* (Guduchi) stem,<sup>[10]</sup> *Withania somnifera* (Ashwagandha) root<sup>[11,12]</sup> and *Zingiber officinale* (Shunthi) rhizome.<sup>[13,14]</sup>

Histopathological study also indicated that the pretreatment with test formulation provided significant cyto-protection against ethanol and acetic acid-induced acute and chronic gastric ulcers in rats respectively.

On basis of present data, it can be concluded that Herbo-mineral formulation possesses promising anti-ulcer activity against exposure to noxious agents like ethanol and acetic acid. The observed effect may be due to synergistic anti-oxidant property of ingredients of the Herbo-mineral formulation.

## ACKNOWLEDGEMENT

Authors are sincerely thankful to the management of Vasu Healthcare Pvt. Ltd. and Babaria Institute of Pharmacy for providing the necessary facilities for conducting the study.

## REFERENCES

1. Shah JS, Patel JR. Anti-ulcer activity of Lucer against experimentally induced gastric ulcers in rats. *Ayu* 2012;33:314-6.
2. Ligha AE, Fawehinmi HB. Protection by liquorice in alcohol induced gastric mucosa damage. *Pakistan J Nutr* 2009;8:1532-6.
3. Bujanda L. The effects of alcohol consumption upon the gastrointestinal tract. *Am J Gastroenterol* 2000;95:3374-82.
4. Bode C, Bode JC. Alcohol's role in gastrointestinal tract disorders. *Alcohol Health Res World* 1997;21:76-83.
5. Grendell JH, Friedman SL, McQuaid KR. Current diagnosis and treatment in gastroenterology. 2nd ed. New York: McGraw-Hill Professional; 2003.p.639-63.
6. Kumar AVSP, Jonnalagadda VP, Joy JM, Prathyusha S, Lakshmi M. Pharmacognostical, phytochemical and pharmacological evaluation for the antiulcer activity of Polyherbal suspension. *Journal of Pharmacognosy and Phytochemistry* 2013;2:128-35.
7. Al-Rehaily AJ, Al-Howiriny TA, Al-Sohaibani MO, Rafatullah S. Gastroprotective effects of 'Amla' *Embllica officinalis* on in vivo test models in rats. *Phytomedicine* 2002;9:515-22.

8. Bhatnagar M, Sisodia SS. Antisecretory and antiulcer activity of *Asparagus racemosus* Willd. against indomethacin plus pyloric ligation-induced gastric ulcer in rats. *J Herb Pharmacother* 2006;6:13-20.
9. Fatima N, Ahmad M, Imran H, Syed S, Kar ZY. Antiulcerogenic and toxicological studies of *Glycyrrhiza glabra* roots available in local market of Karachi. *Karachi University Journal of Science* 2008;36:5-8.
10. Chandan NG, Deb T, Bhargavi SM. Evaluation of anti-ulcer activity of *Tinospora cordifolia* in albino rats. *Int J Pharm Bio Sci* 2013;4:78-85.
11. Bhatnagar M, Sisodia SS, Bhatnagar R. Antiulcer and antioxidant activity of *Asparagus racemosus* Willd and *Withania somnifera* Dunal in rats. *Ann N Y Acad Sci* 2005;1056:261-78.
12. Raghuveer B, Chakarvarthy K, Raju SU. Evaluation of preventive effect of *Withania somnifera* root extract against ethanol induced ulcers in rats. *Int J Bioassays* 2013;2:938-41.
13. Wang Z, Hasegawa J, Wang X, Matsuda A, Tokuda T, Miura N, et al. Protective effects of ginger against aspirin-induced gastric ulcers in rats. *Yonago Acta Medica* 2011;54:11-9.
14. Al-Yahya MA, Rafatullah S, Mossa JS, Ageel AM, Parmar NS, Tariq M. Gastro-protective activity of ginger *Zingiber officinale* rosc., in albino rats. *Am J Chin Med* 1989;17:51-6.
15. Chuneekar KC, Pandey GS, Bhavprakash. Nighantu of Shri Bhavamishra. Varanasi, India: Chaukhambha bharati academy; 2002.p.165.
16. Hewageegana HGSP, Ariyawansa HAS, Ratnasooriya WD. Gastroprotective activity of the paste of *Evolvulus alsinoides* L. (vishnukranti kalka) in rats. *Vidyadaya J Sci* 2006;13:23-31.
17. Paget GE, Barnes JM. Evaluation of drug activities. In: Lawrence DR, Bacharach AL, editors. *Pharmacometrics*. Vol. I. New York: Academic Press; 1964. p. 161.
18. Vogel HG. Drug discovery and evolution, pharmacological assay. 2nd ed. Germany: Springer, 2002, p.759-872.
19. Ganguly AK, Bhatnagar OP. Effect of bilateral adrenalectomy on production of restraint ulcers in the stomach of albino rats. *Can J Physiol Pharmacol* 1973;51:748-50.
20. Corne SJ, Morrissey SM, Woods RJ. Proceedings: A method for the quantitative estimation of gastric barrier mucus. *J Physiol* 1974;242:116P-7P.
21. Slater TF, Sawyer BC. The stimulatory effects of carbon tetrachloride and other halogenoalkanes on peroxidative reactions in rat liver fractions *in vitro*. General features of the systems used. *Biochem J* 1971;123:805-14.
22. Beutler E. Red cell metabolism: A manual of Biochemical methods. New York: Grune and Stratton; 1971. p. 9-16.
23. Misra HP, Fridovich I. The role of superoxide anion in the autooxidation of epinephrine and a simple assay for superoxide dismutase. *J Biol Chem* 1972;247:3170-5.
24. Goldblith SA, Proctor BE. Photometric determination of catalase activity. *J Biol Chem* 1950;187:705-9.
25. Okabe S, Roth JL, Pfeiffer CJ. A method for experimental, penetrating gastric and duodenal ulcers in rats, observations on normal healing. *Am J Dig Dis* 1971;16:277-84.
26. Shetty R, Kumar KV, Naidu MUR, Ratnakar KS. Effect of *Ginkgo biloba* extract on ethanol-induced gastric mucosal lesions in rats. *Ind J Pharmacol* 2000;32:313-7.
27. Martin MJ, Marhuenda M, Perez-Guerrero C, Franco JM. Antiulcer effect of naringin on gastric lesions induced by ethanol in rats. *Pharmacology* 1994;49:144-50.
28. Qin Z, Chen C. Synergistic action of famotidine and chlorpheniramine on acetic acid-induced chronic gastric ulcer in rats. *World J Gastroenterol* 2005;11:7203-7.

\*\*\*\*\*